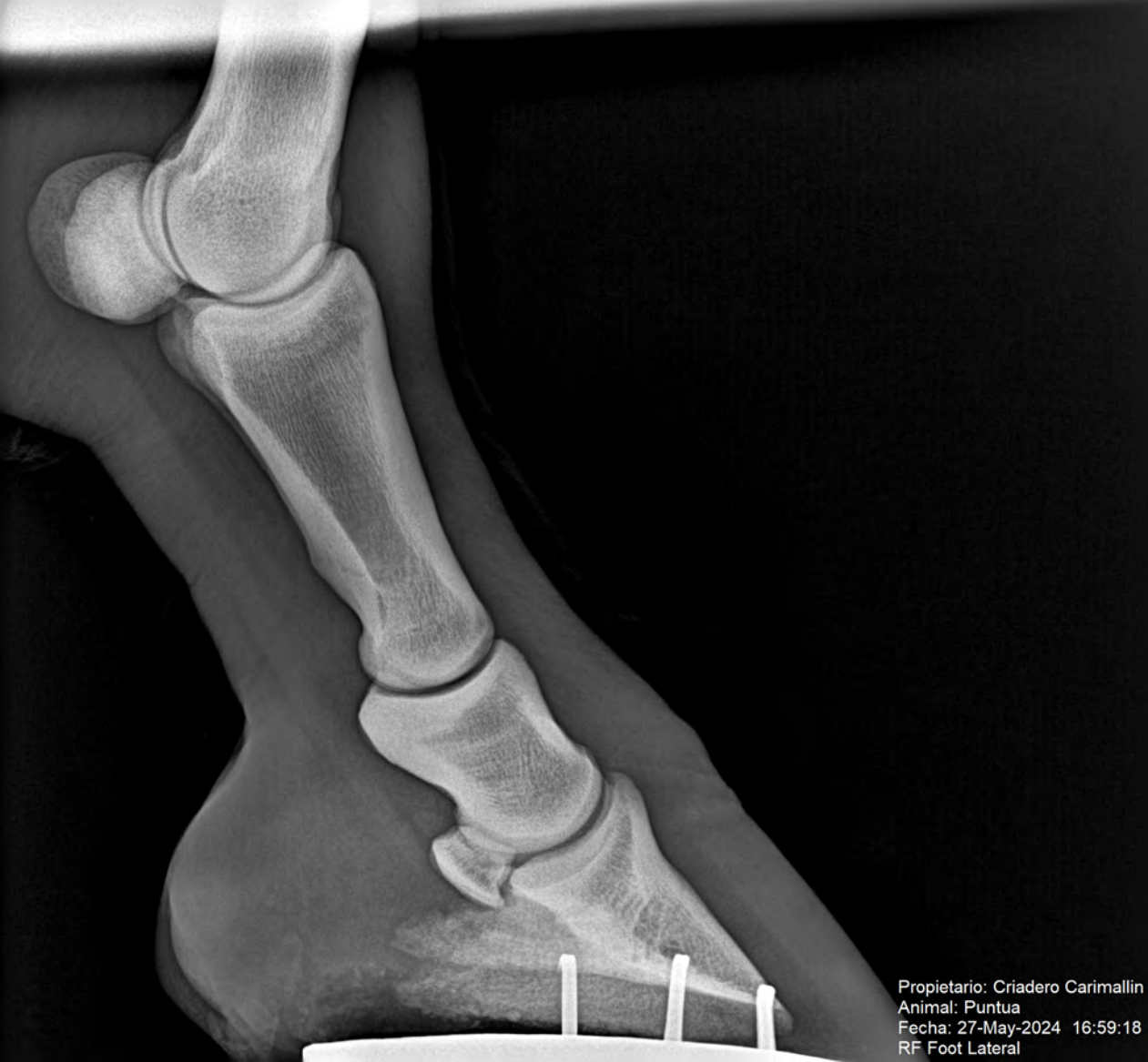



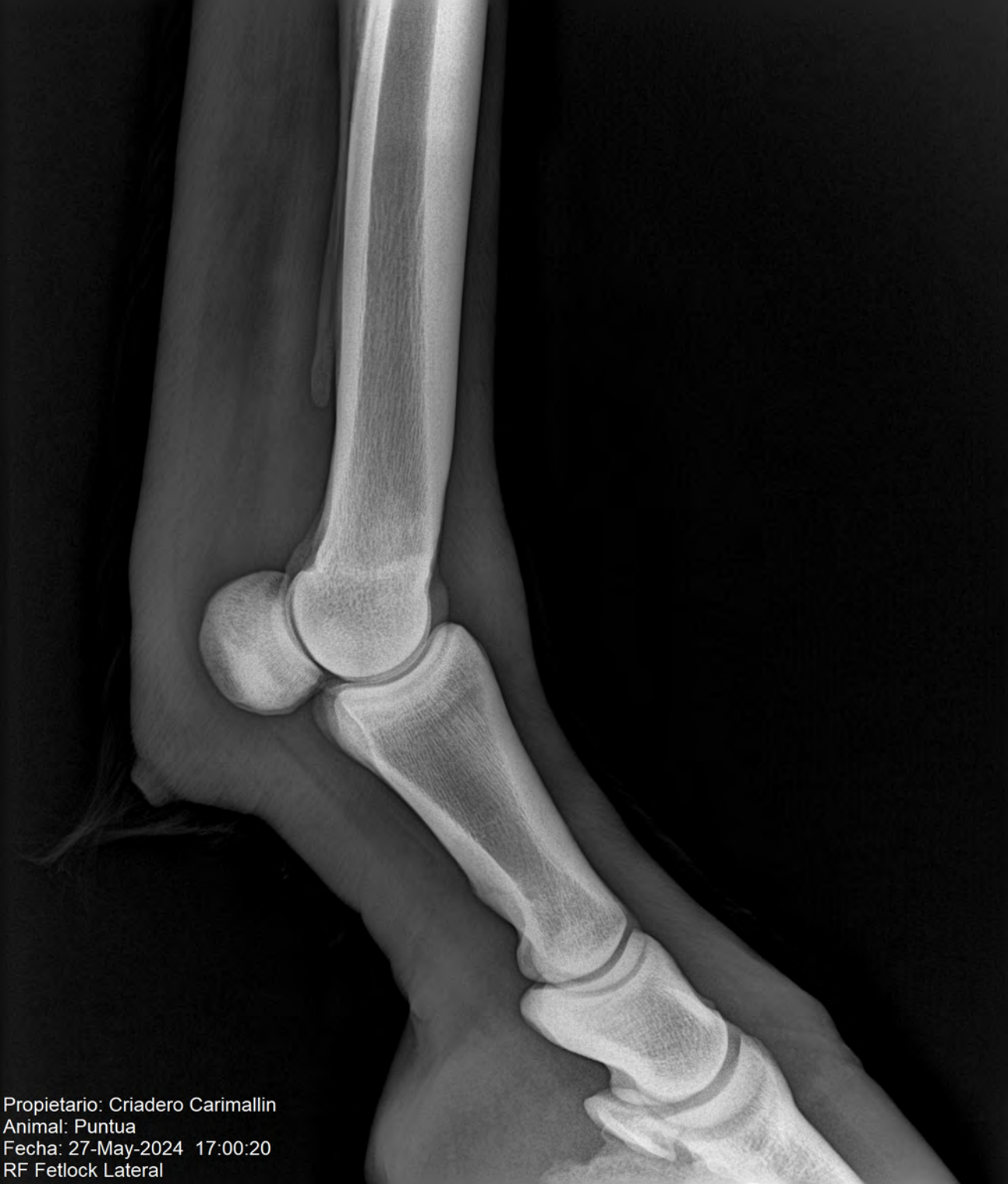
Propietario: Criadero Carimallin
Animal: Puntua
Fecha: 27-May-2024 16:59:18
RF Foot Lateral

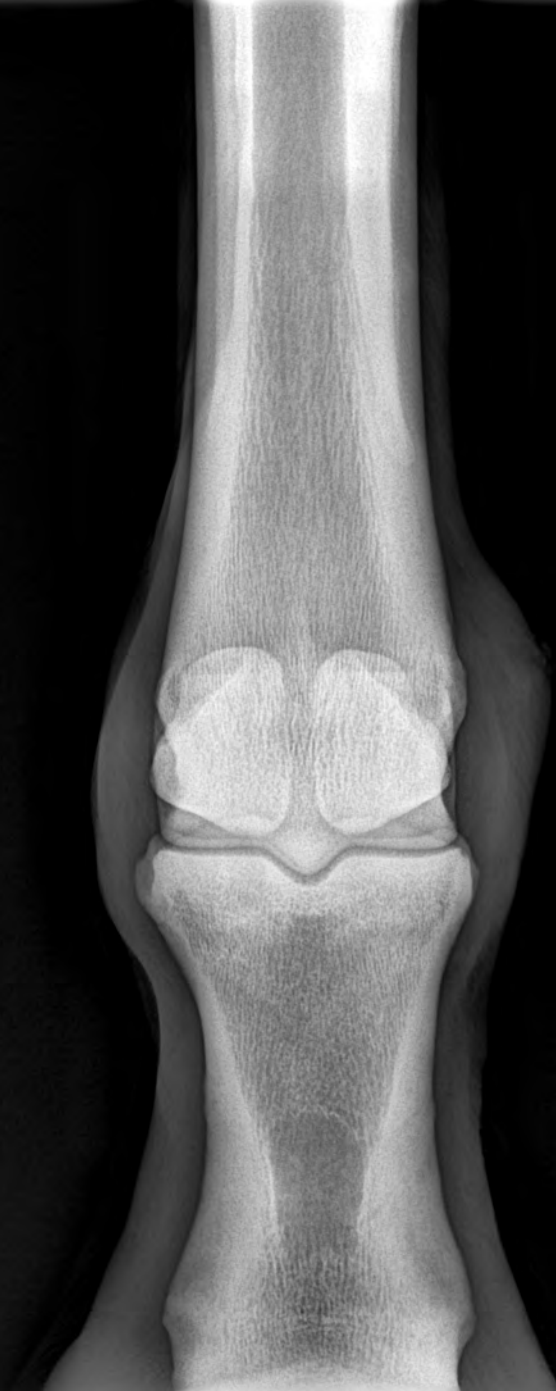

Propietario: Criadero Carimallin
Animal: Puntua
Fecha: 27-May-2024 16:59:44
RF Foot DP

This image shows a dorsal view of a horse's hoof with a radiographic overlay. The hoof is positioned vertically, with the coronary band at the top and the hoof wall at the bottom. The radiographic overlay is a grayscale image that highlights the internal structures of the hoof, including the hoof wall, the coronary band, the hoof sole, and the hoof frog. The overlay is centered on the hoof and extends slightly beyond its edges. The background is black, and the hoof itself is a light gray color. The radiographic overlay is a darker gray color, providing a clear contrast with the hoof's natural color. The overlay shows the internal structure of the hoof, including the hoof wall, the coronary band, the hoof sole, and the hoof frog. The overlay is centered on the hoof and extends slightly beyond its edges. The background is black, and the hoof itself is a light gray color. The radiographic overlay is a darker gray color, providing a clear contrast with the hoof's natural color.

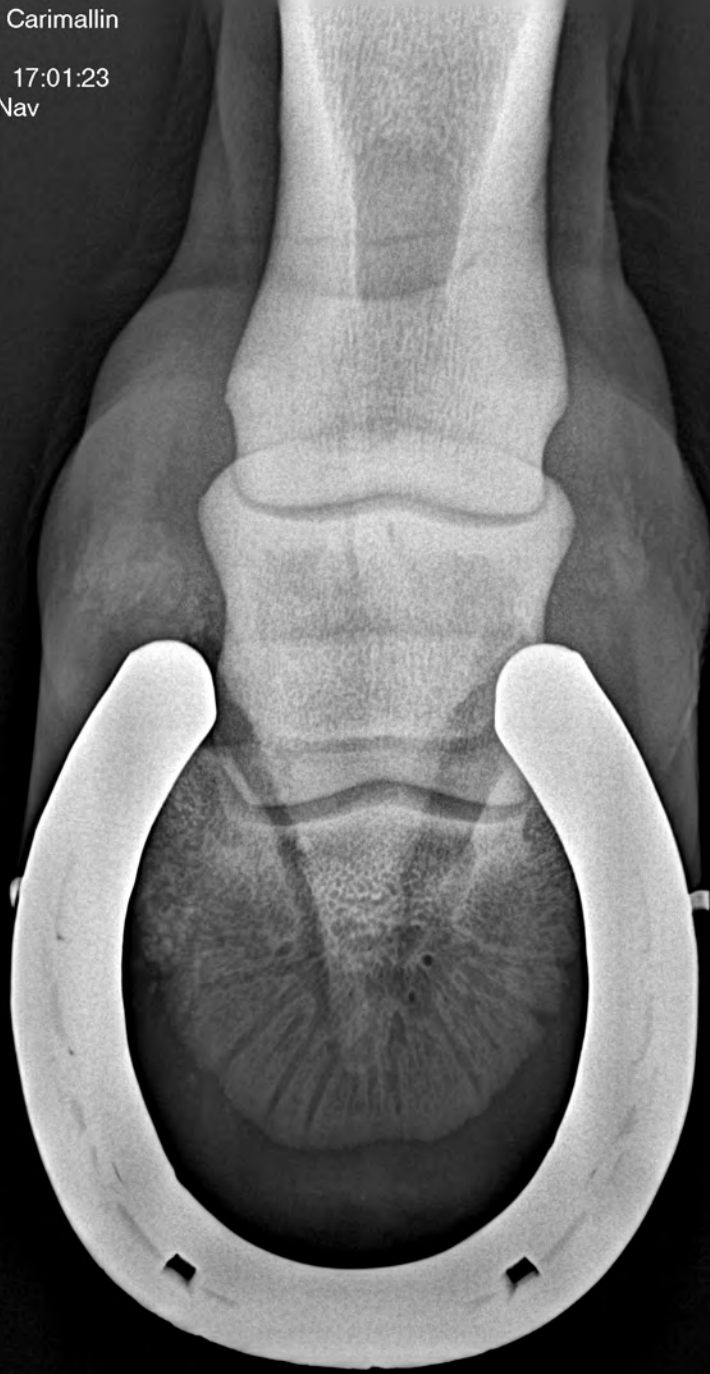

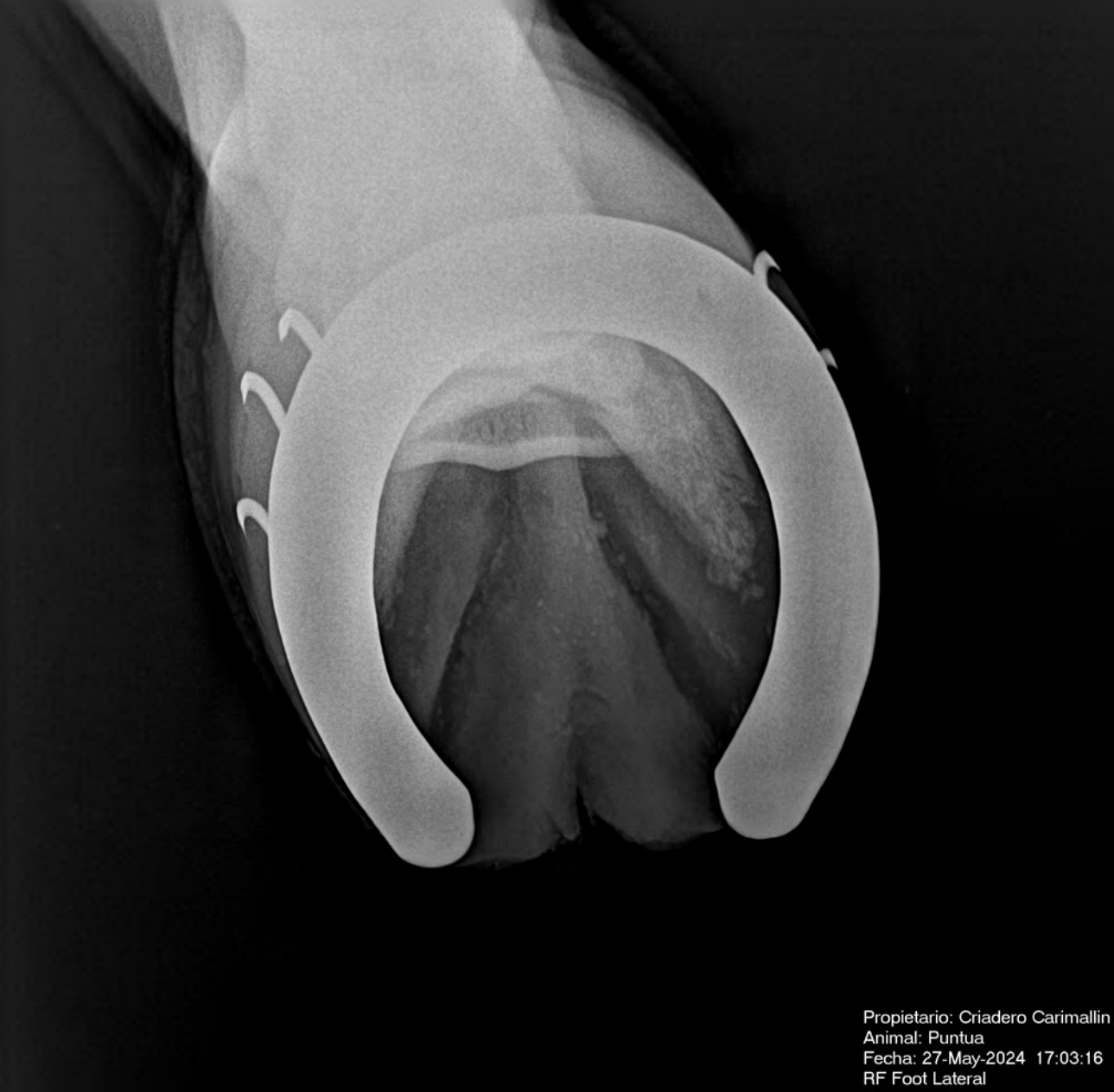Propietario: Criadero Carimallin
Animal: Puntua
Fecha: 27-May-2024 17:00:20
RF Fetlock Lateral



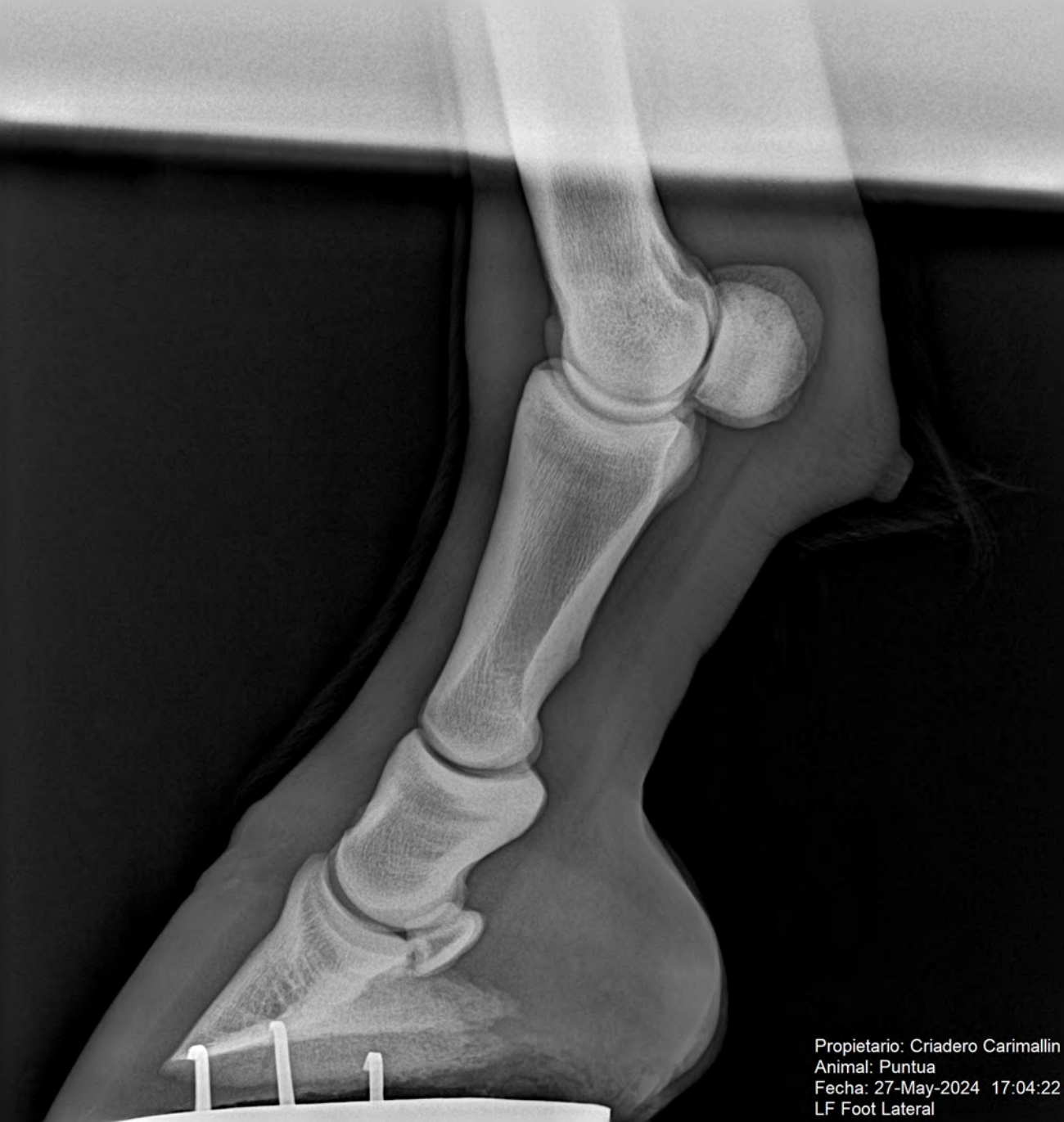Propietario: Criadero Carimallin
Animal: Puntua
Fecha: 27-May-2024 17:00:36
RF Fetlock DP

Propietario: Criadero Carimallin
Animal: Puntua
Fecha: 27-May-2024 17:01:23
RF Foot 60 Deg DP Nav






Propietario: Criadero Carimallin
Animal: Puntua
Fecha: 27-May-2024 17:03:16
RF Foot Lateral

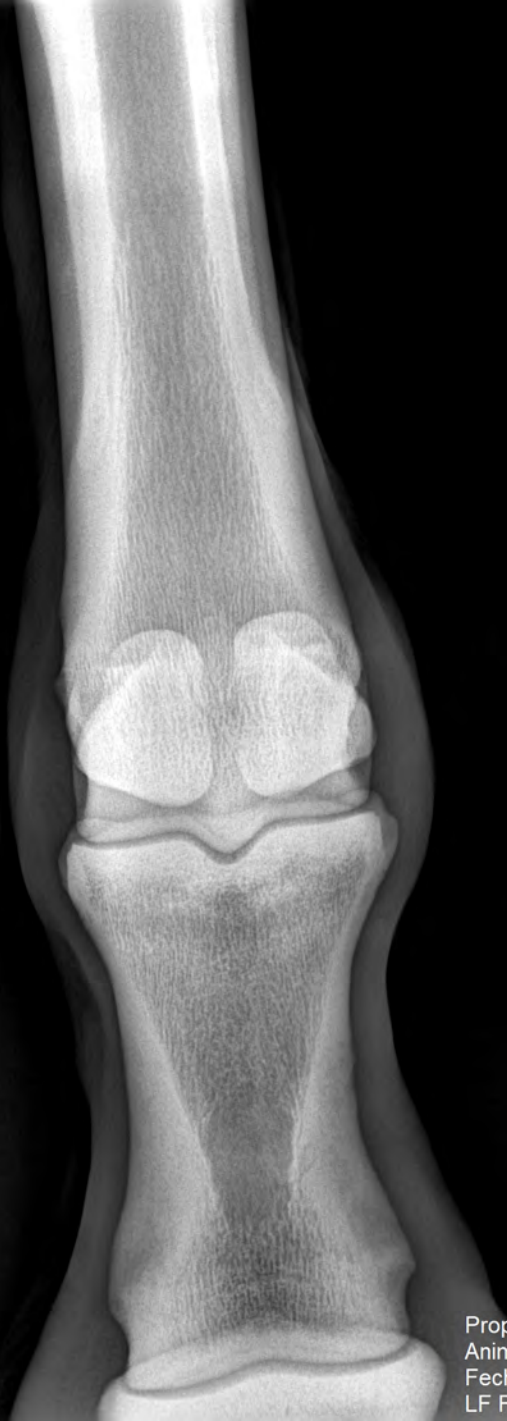

Propietario: Criadero Carimallin
Animal: Puntua
Fecha: 27-May-2024 17:04:22
LF Foot Lateral

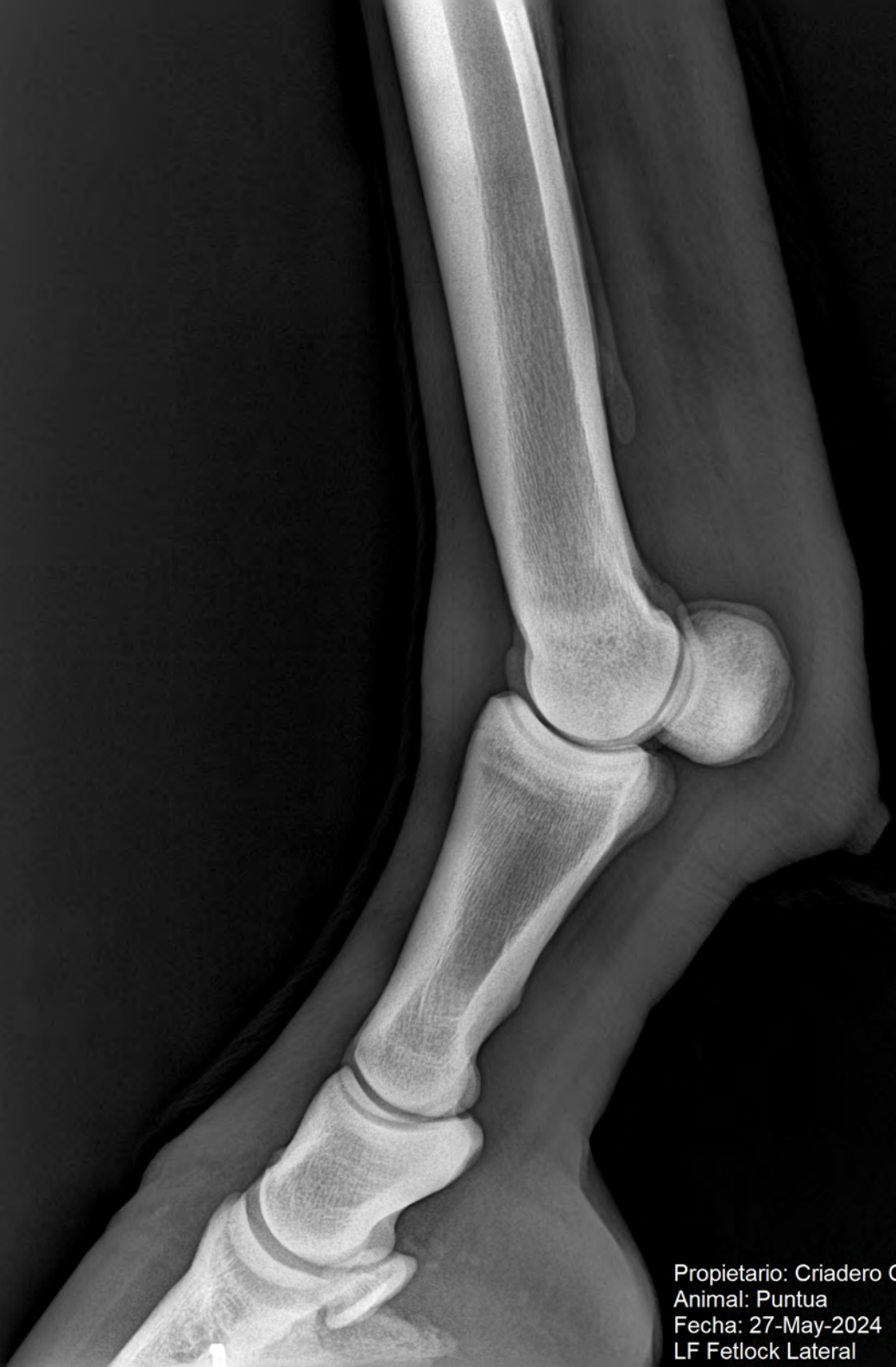

Propietario: Criadero Carimallin
Animal: Puntua
Fecha: 27-May-2024 17:04:44
LF Foot DP

This image shows a dorsal view of a horse's hoof with radiographs of the distal interphalangeal (DIP) joint. The hoof wall is visible on the sides, and the internal structures of the hoof, including the hoof capsule and the DIP joint, are clearly visible. The radiographs show the bones of the joint, including the distal phalanx and the proximal phalanx. The joint space is visible, and there is no obvious evidence of joint disease or injury.

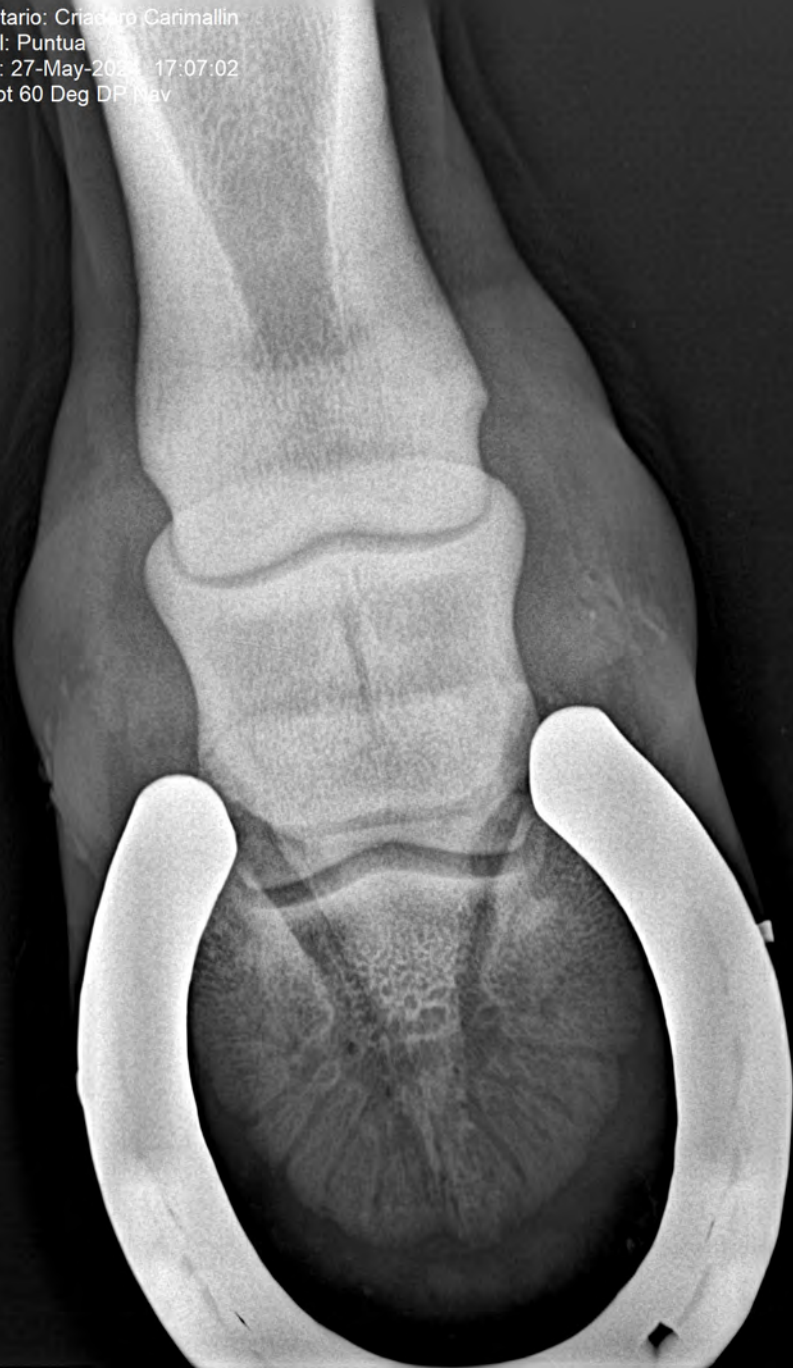

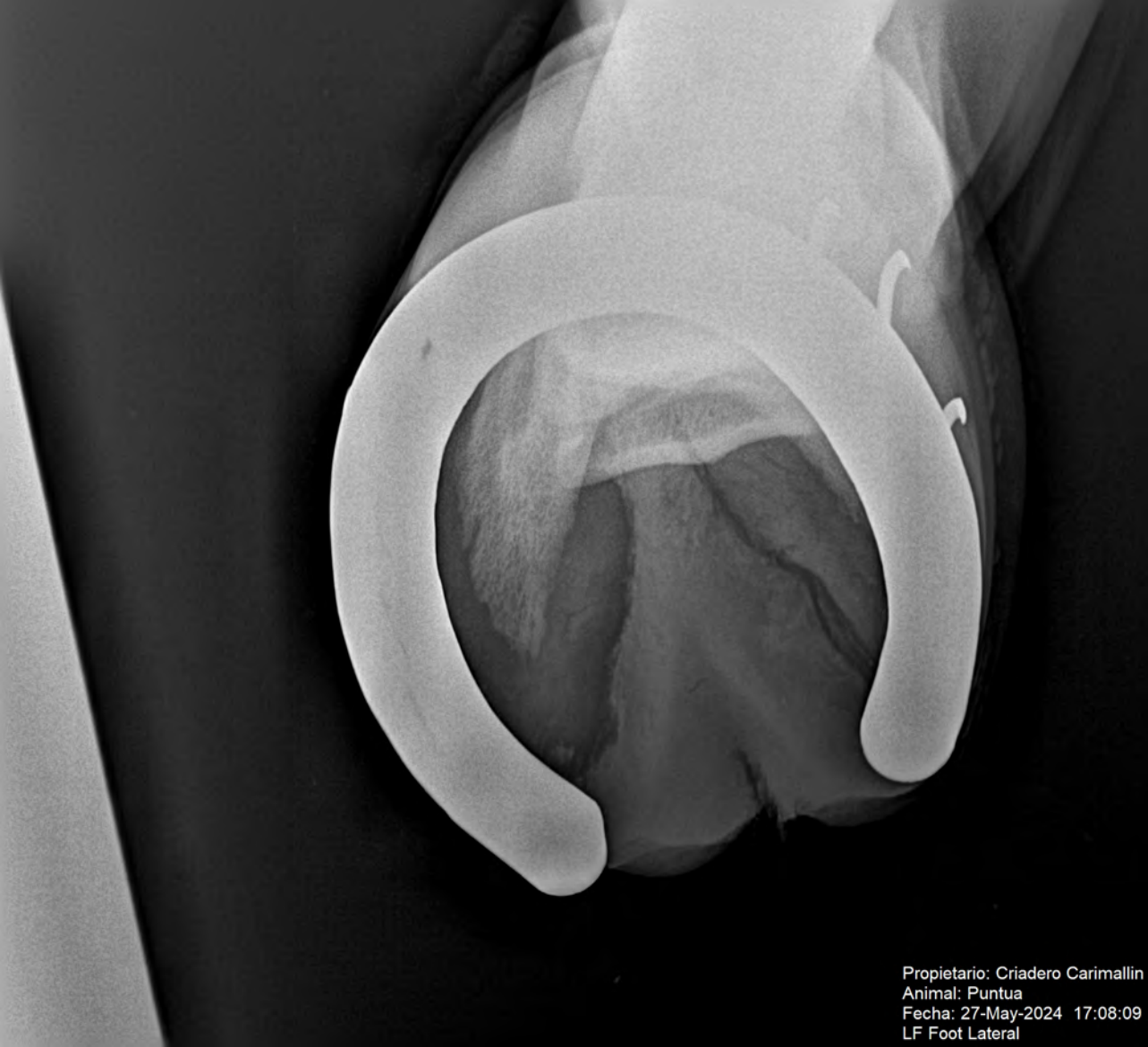Propietario: Criadero Carimallin
Animal: Puntua
Fecha: 27-May-2024 17:05:23
LF Fetlock DP



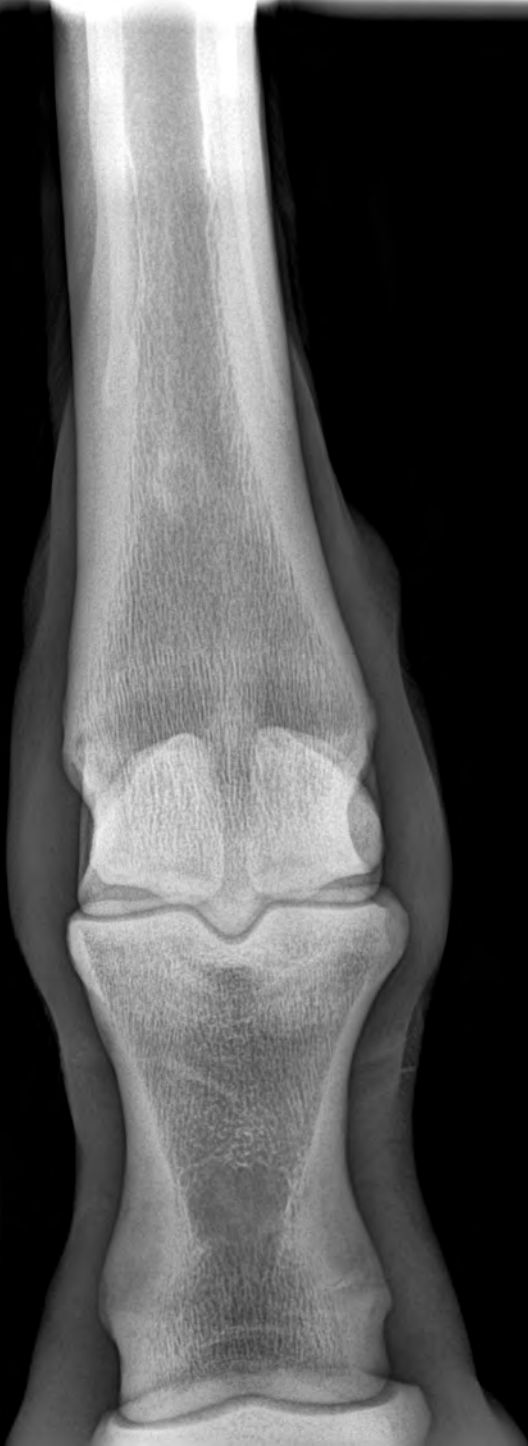Propietario: Criadero Carimallin
Animal: Puntua
Fecha: 27-May-2024 17:05:40
LF Fetlock Lateral

Propietario: Criadero Carimallin
Animal: Puntua
Fecha: 27-May-2024 17:07:02
LF Foot 60 Deg DR Nav

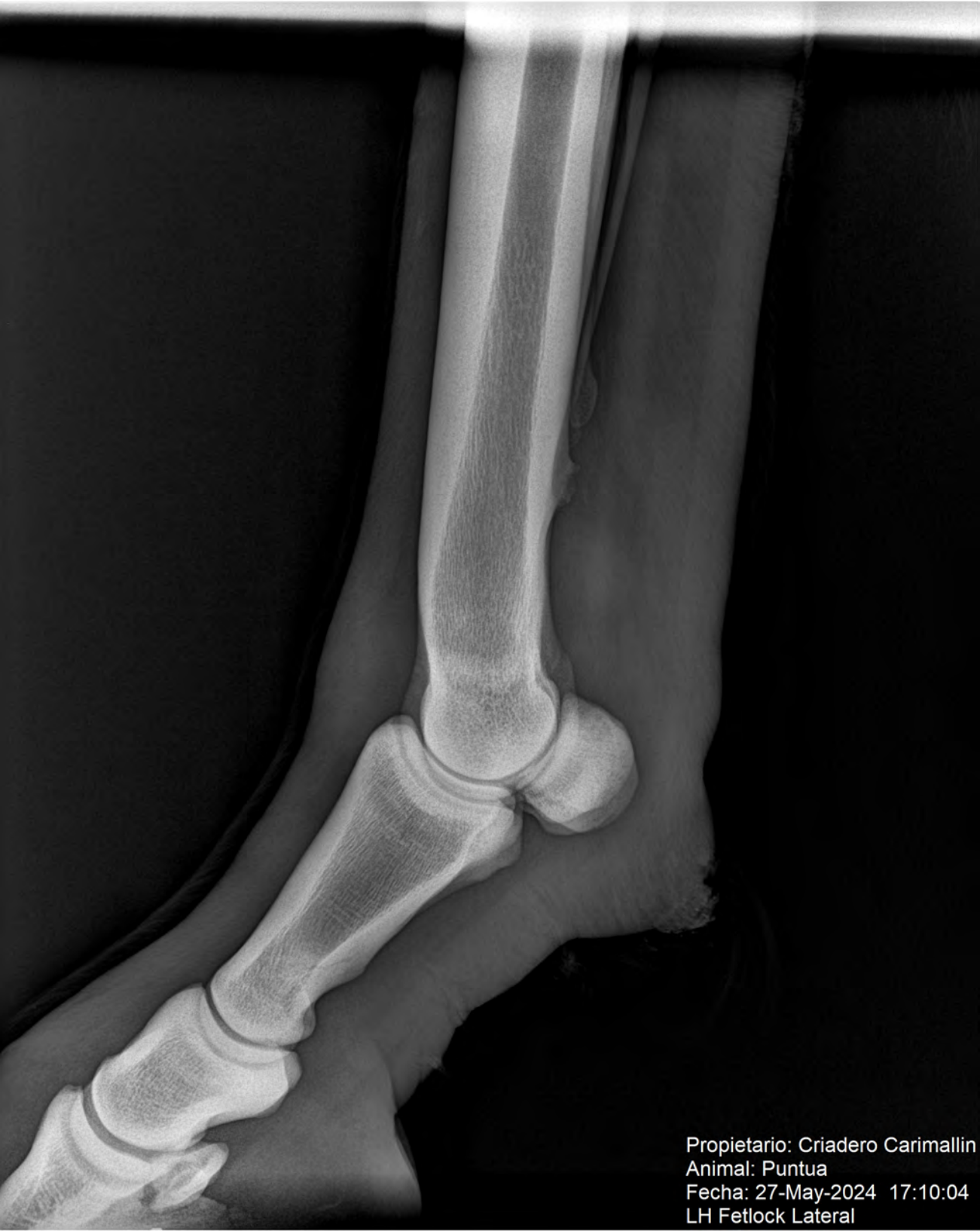



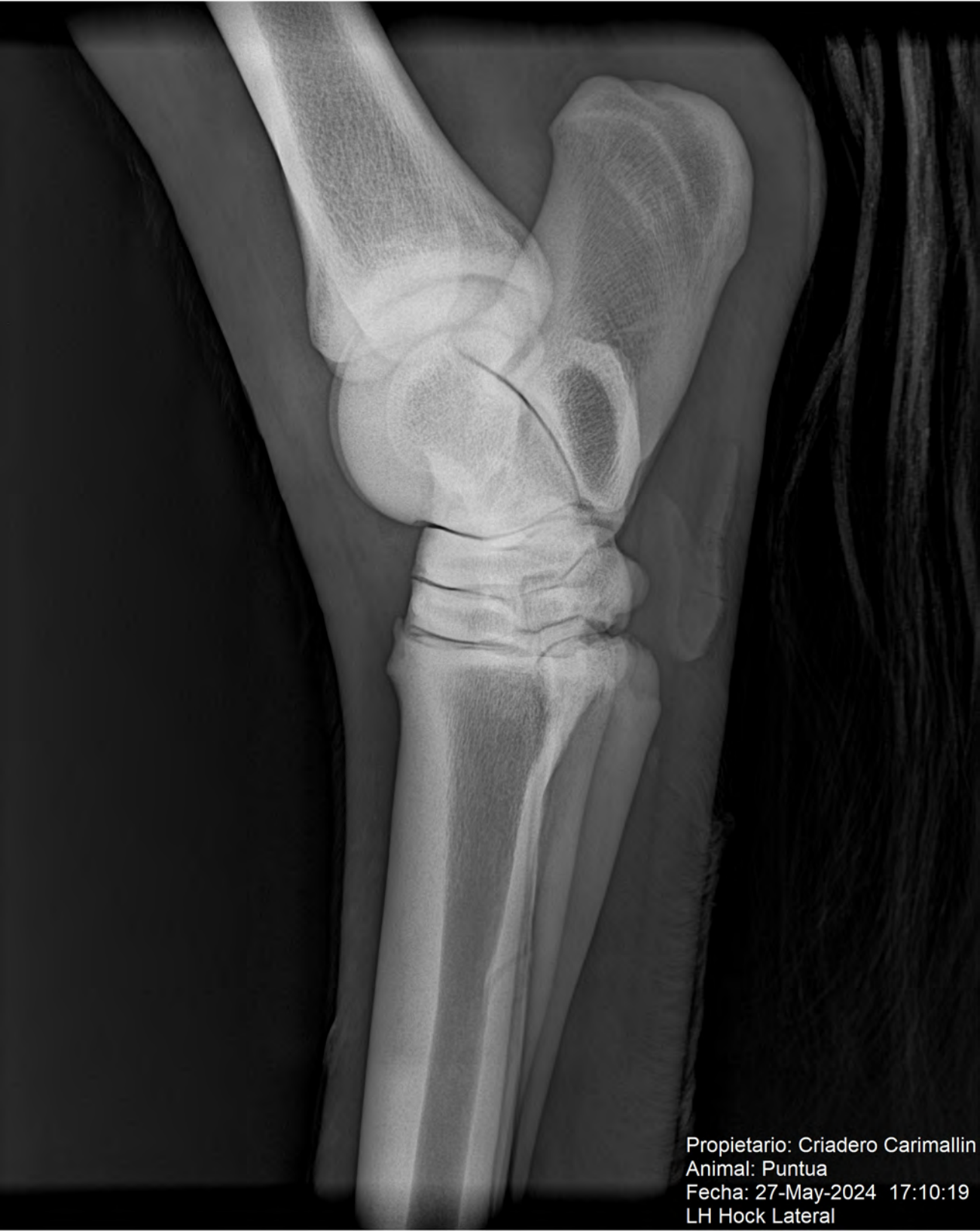Propietario: Criadero Carimallin
Animal: Puntua
Fecha: 27-May-2024 17:08:09
LF Foot Lateral



Propietario: Criadero Carimallin
Animal: Puntua
Fecha: 27-May-2024 17:09:35
LH Fetlock DP

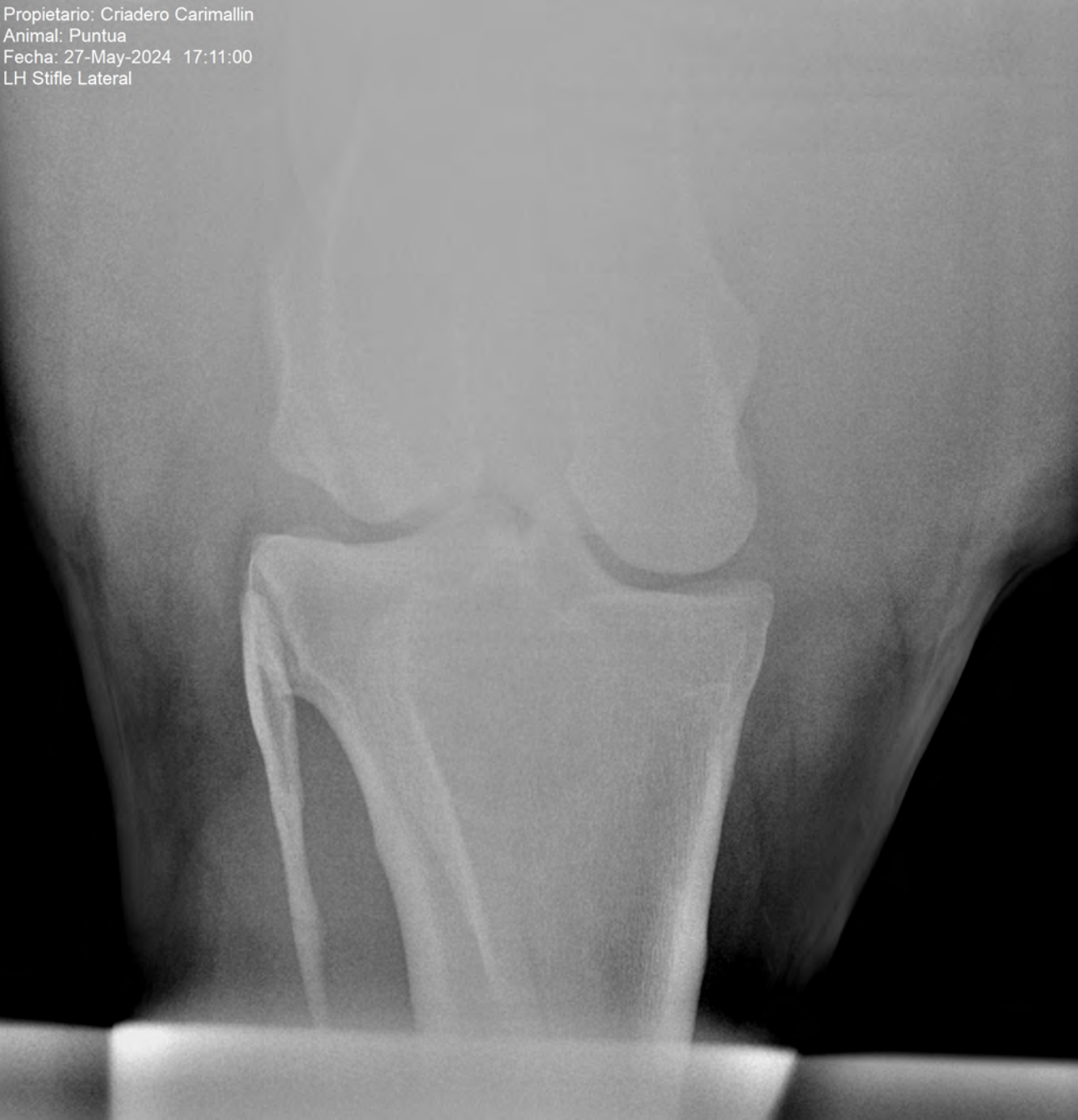

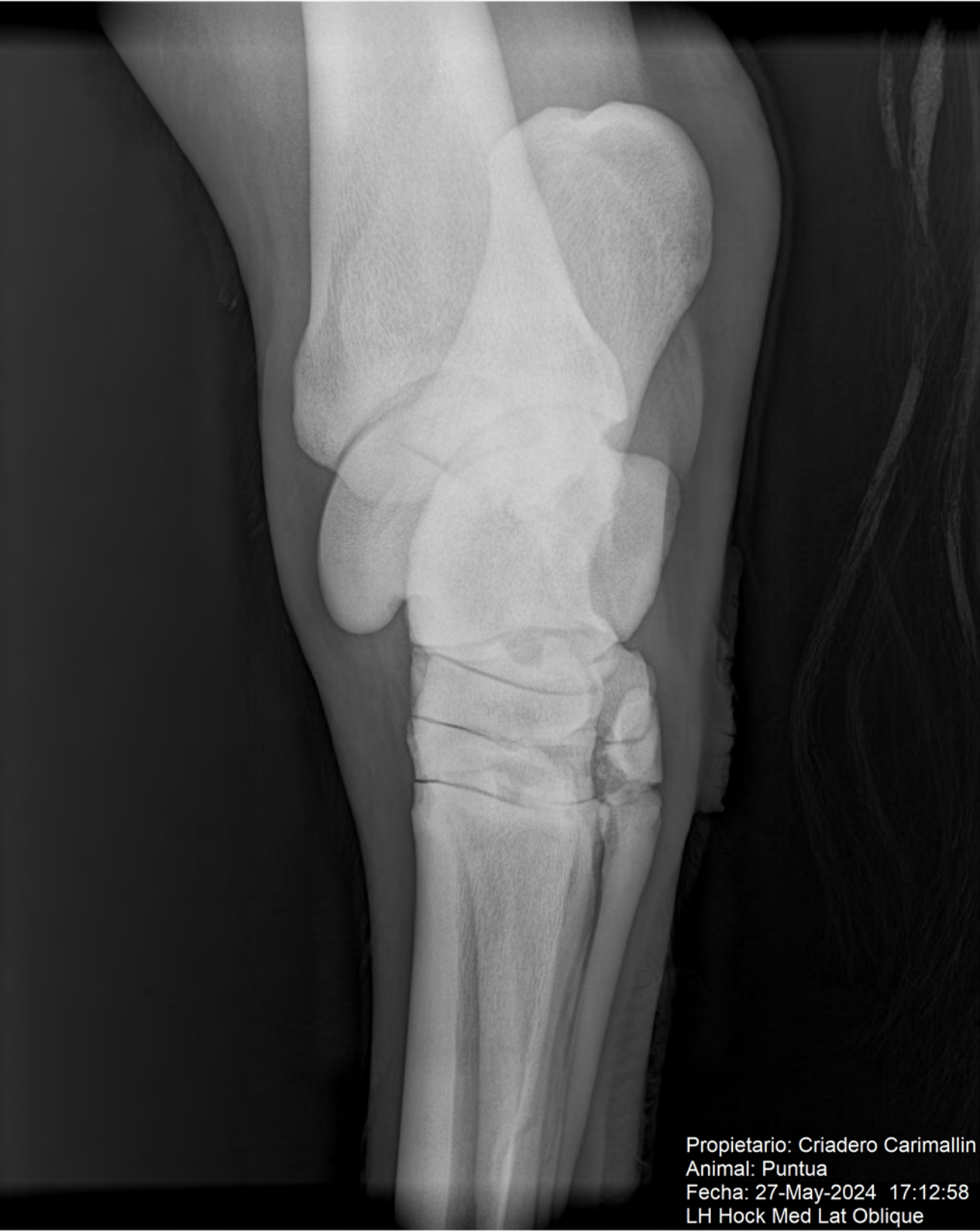Propietario: Criadero Carimallin
Animal: Puntua
Fecha: 27-May-2024 17:10:04
LH Fetlock Lateral



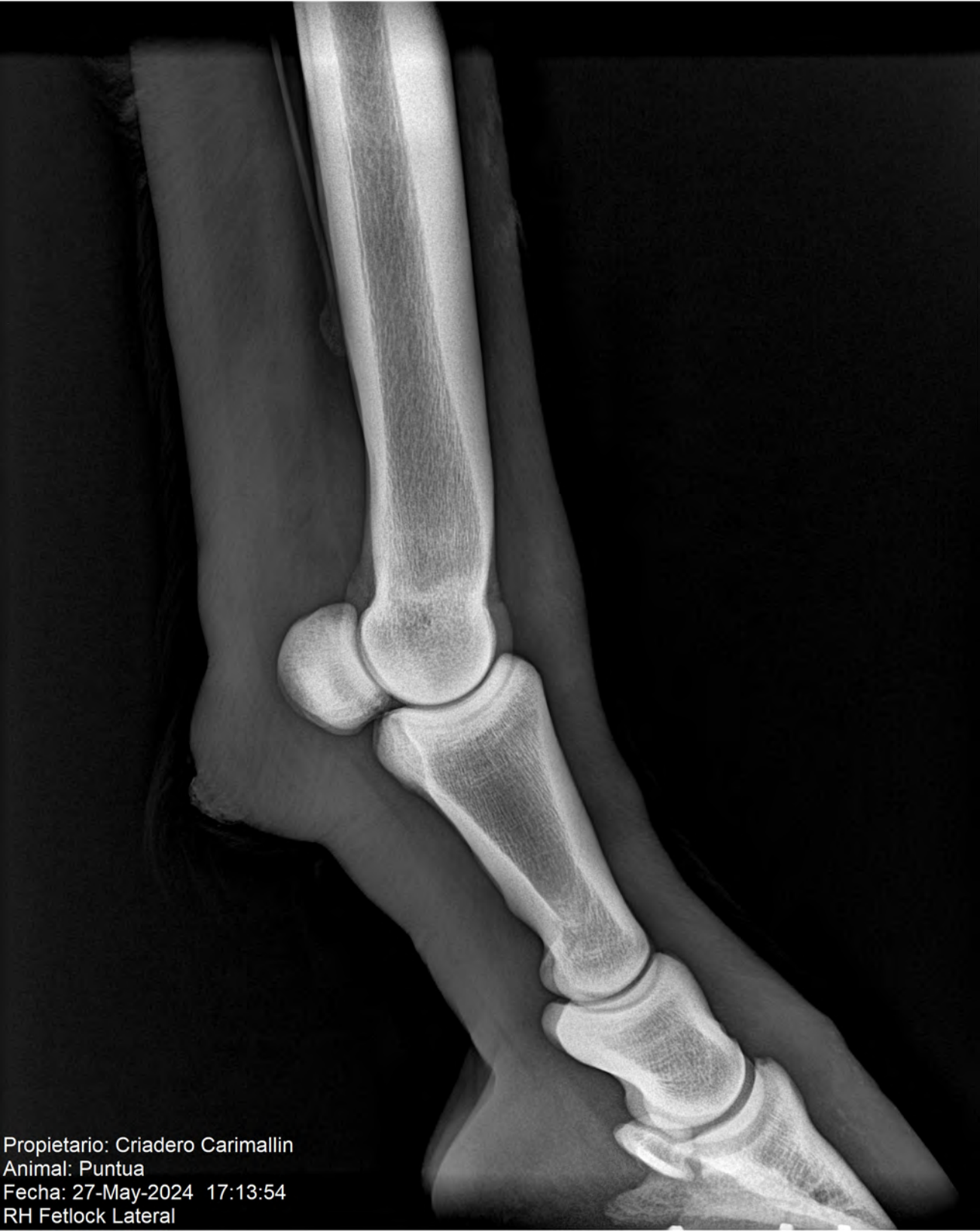Propietario: Criadero Carimallin
Animal: Puntua
Fecha: 27-May-2024 17:10:19
LH Hock Lateral

Propietario: Criadero Carimallin
Animal: Puntua
Fecha: 27-May-2024 17:11:00
LH Stifle Lateral

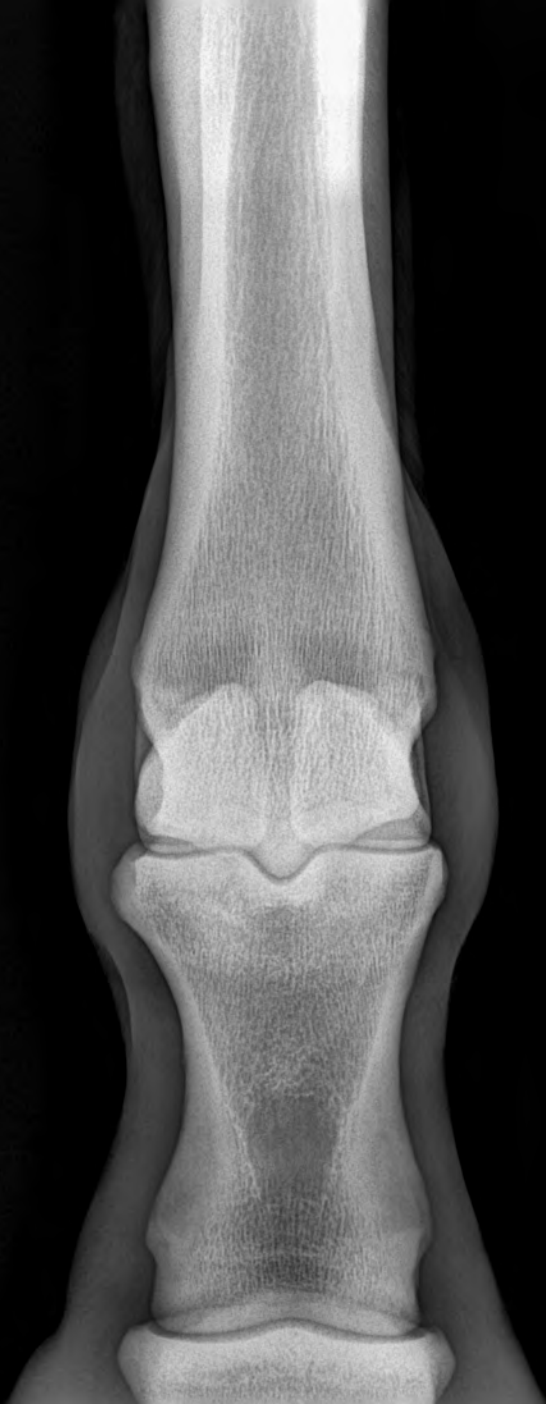



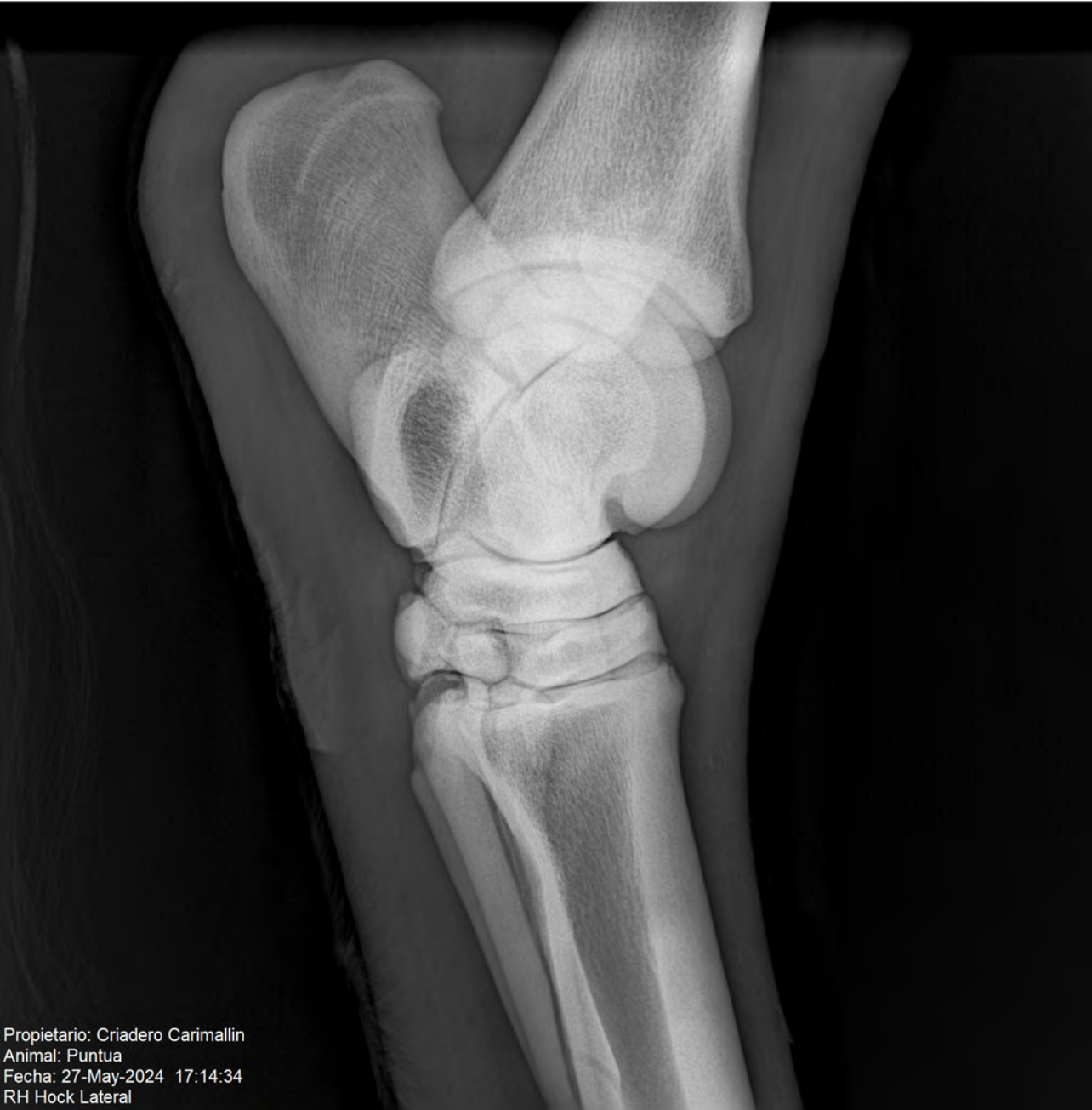Propietario: Criadero Carimallin
Animal: Puntua
Fecha: 27-May-2024 17:12:58
LH Hock Med Lat Oblique



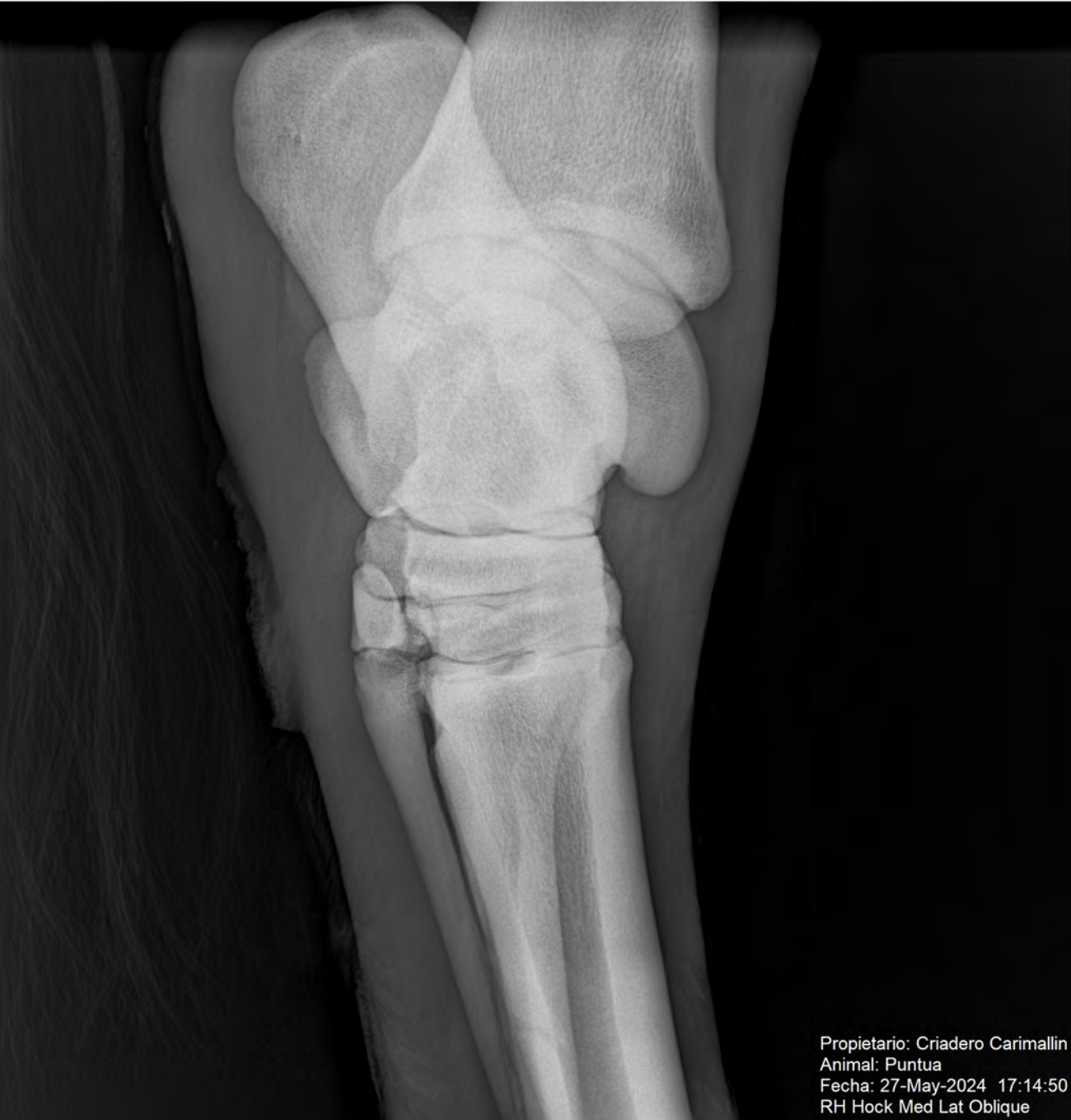Propietario: Criadero Carimallin
Animal: Puntua
Fecha: 27-May-2024 17:13:54
RH Fetlock Lateral



Propietario: Criadero Carimallin
Animal: Puntua
Fecha: 27-May-2024 17:14:19
RH Fetlock DP



Propietario: Criadero Carimallin
Animal: Puntua
Fecha: 27-May-2024 17:14:34
RH Hock Lateral



Propietario: Criadero Carimallin
Animal: Puntua
Fecha: 27-May-2024 17:14:50
RH Hock Med Lat Oblique

